Histopathological and Cytogenetic study of benzidine effects in Laboratory mouse (*Mus musculus*).

Tabark L. Abdalsamed and Karim H. Thamir Al-Derawi

Department of Biology/science College-Basrah University

Abstract

The present study was carried out to determine the effects of benzidine on male mice(*Mus musculus*). Animals were treated once via interperetonium(ip) to concentration (25,50 &100)mg/kg benzidine for (3&5)months. The histopathlogical changes of the liver results showed degeneration, infiltration of inflammatory cells aggregate of Kupffer cells . As well as observed congestion in blood vessels, necrosis, granuloma, hemorrhage, cytoplasmic vaculation and revealed fatty droplets and increased of mucus poly saccharide deposition compared with control animals. On the other hand increased in the chromosome aberrations includes ring chromosome, centromeric break, dicentric chromosome and chromatid break.

Key words: Benzidine, histopathological

1. Introduction

Benzidine used mainly as intermediates in the production of azo dyes, symmetrically or asymmetrically coupled products can be produced by simultaneous or successive diazotization respectively [(1).] Benzidine has been used since the 1850s as the reagent base for the production of a large number of dyes, particularly azo dyes for wool, cotton, and leather [(2).] In the past, benzidine also has been used in clinical laboratories for detection of blood, as a rubber compounding agent, in the manufacture of plastic films, for detection of hydrogen peroxide in milk, and for quantitative determination of nicotine. Most of these uses have been discontinued because of toxicological concerns. Some dyes used as stains for microscopy and similar laboratory applications may contain benzidine as an impurity [(3,4).] Benzidine was tested in mice, rats, hamsters and dogs by oral administration, in mice and rats by subcutaneous administration and in rats by inhalation and intraperitoneal injection.

Following oral administration to newborn and adult mice of different strains and of both sexes, it significantly increased the incidence of benign and malignant liver tumours. In female rats, it is markedly increased the incidence of mammary tumours; in male and female hamsters, it increased the incidence of liver tumours; and in dogs it produced bladder tumours ([5].
The subcutaneous administration of benzidine or its sulfate to mice produced significant increases in the incidence of benign and malignant liver tumours. In rats, benzidine produced a high incidence of Zymbal gland tumours; colonic tumours were also reported. The intraperitoneal administration of benzidine to rats resulted in a marked increase in the incidence of mammary and Zymbal gland tumours [6]. In workers exposed to benzidine, the accumulation of mutant p53 protein increased with increasing exposures[7]. Significant increases in the incidence of chromosomal aberrations in peripheral lymphocytes have been observed in workers exposed to benzidine or benzidine-based dyes [8]. Similarly, benzidine induced DNA lesions in *TP53* in the bladder, liver, and lung of exposed rats and increased the frequency of micro nucleated bone-marrow cells and induced unscheduled DNA synthesis in mice, and increased DNA strand-breaks in the liver of exposed rats. [9],

2.Materials and methods:

Male mice weighting (30-40 g.) purchased from animals house of science college, they were kept with standard condition (pallated and water ed libitum) and a 12: 12 hrs. Light-dark cycle. Total number of animals male (32) mice divided into (4) groups with (8) mice in each. The animals of control group (G1) treated only normal saline interaperitoneally for. Animals of G2, G3 and G4 were treated with benzidine interaperitoneally 25, 50 and 100 mg/kg respectevely. All treated animal of G2, G3 and G4 groups were injected only one time at the beginning of the experiment. After (3 & 5) months, the male mice were anensthetized with ether, liver and bone marrow were taken from all animals, liver samples immediately fixed in10% neutral buffered formalin fixative. Then, routine histological procedures were conducted [10].
Histological sections of liver were stained with haematoxiline and eosin (H&E), other sections stained with PAS and examined with light microscope, and bone marrow were taken from all animals groups from femurs for examined chromosomes aberrations according to [11].

3. Results:

1-Histological examination

Histological examination of the liver animals control showed central vein and hepatocytes (Fig.1). The histopathological examination of the liver sections was revealed after 3&5 month treatment to the tested benzidine, varieties of lesions were identified in the examined. These lesions appeared to increase with the increasing dose. The histopathological examination of the animals treated with 25mg/kg.b.w. for 3 month showed infiltration of inflammatory cells, liver cells degeneration, vasodilatation in portal vein and enlargement of the sinusoids (Fig.2 & 3) and showed congestion, cell degeneration and enlargement of the sinusoids in animals treated for 5 month(Fig.4 & 5). While in the animals treated with 50 mg/kg.b.w for 3month showed congestion in blood vessels, inflammatory cells around the central vein, necrotic cells and granuloma(Fig.6&7), and showed cytoplasmic vaculation, hemorrhage and congestion in portal vein in the animals treated for 5 month (Fig.8 & 9). Adminstration of benzidine with 100mg/kg.b.w for 3&5 month resulted in the damage of liver structure along with disarrangement of hepatic strands , also showed hemorrhage, more degeneration cells, cytoplasmic vaculation, congestion in portal vein, appear collagenous fiber and fatty globules appear (10 &11 &13).

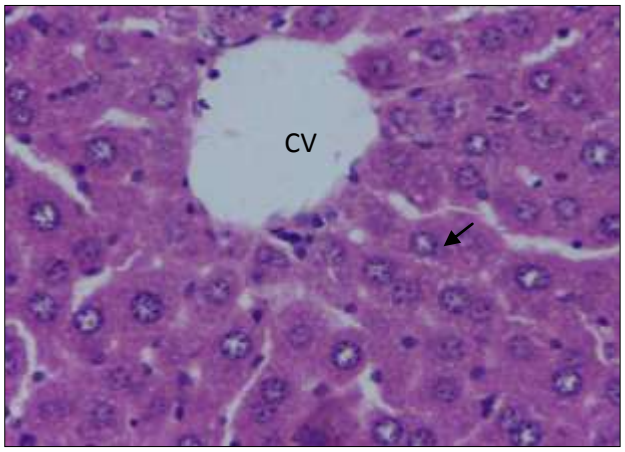

Fig.1: Histological section in liver of control mice, showed central vein(cv) and hepatocytes → (H&E. 400x).

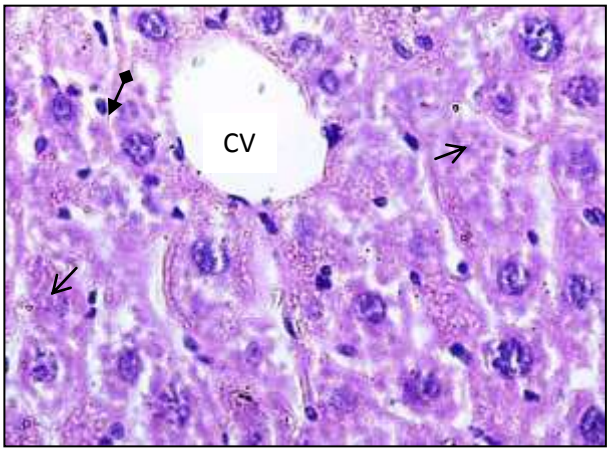

Fig.2: Histological section in liver of the animals treated with 25mg/kg.b.w. of benzidine for 3 month, showed central vein (CV), inflammatory cells ↔ and cell degeneration → (H&E. 400x).

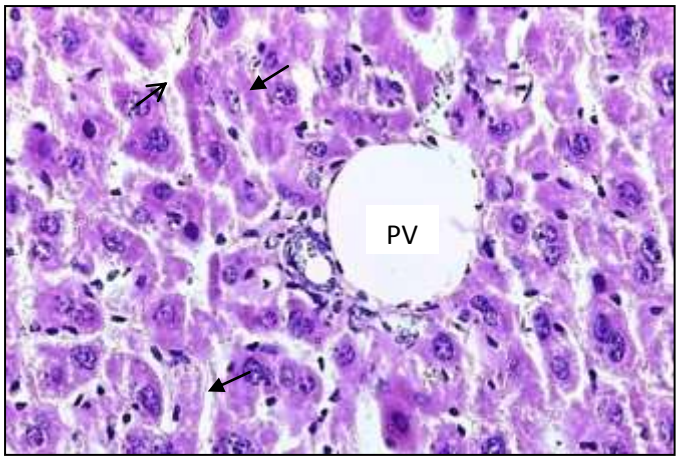

Fig.3: Histological section in liver of the animals treated with 25mg/kg.b.w. of benzidine for 3 month, showed vasodilation in portal vein (PV), enlargement of the sinusoids → and cell degeneration ⟶ (H&E. 400x).

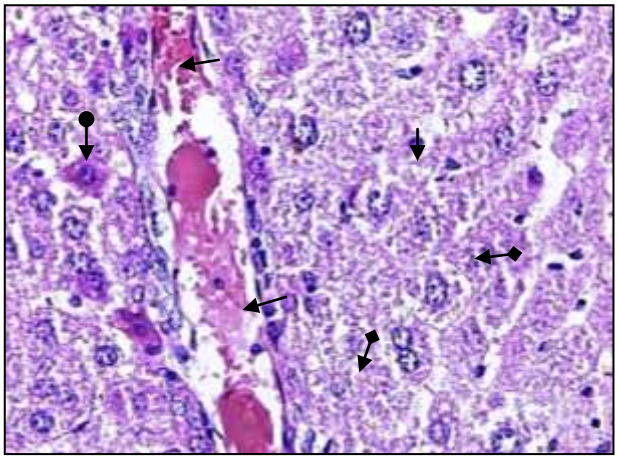

Fig.4: Histological section in liver of the animals treated with 25mg/kg.b.w. of benzidine for 5 month, showed congestion ⟶, acidophilic cytoplasm ●⟶ and cell degeneration ◆⟶ (H&E. 400x).

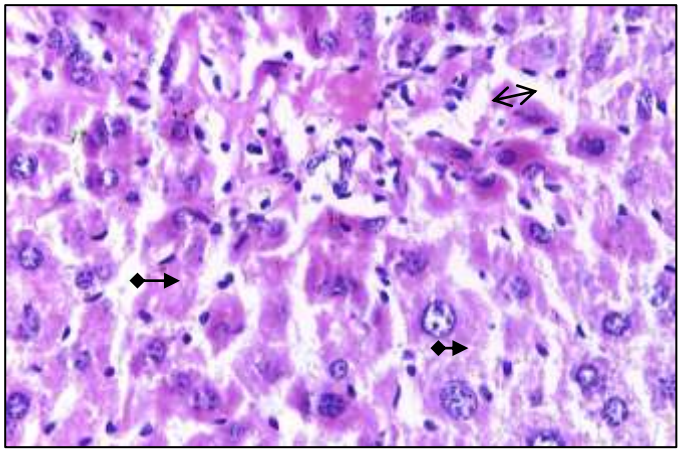

Fig.5: Histological section in liver of the animals treated with 25mg/kg.bw. of benzidine for 5 month, showed cell degeneration ◆⟶, enlargement of the sinusoids ⇔ (H&E. 400x).

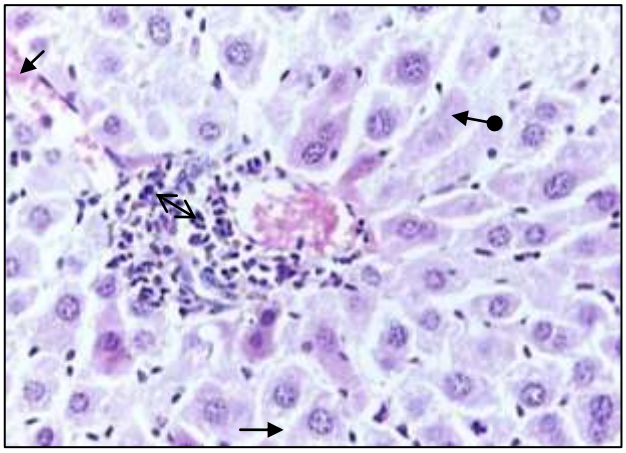

Fig.6: Histological section in liver of the animals treated with 50mg/kg.bw. of benzidine for 3 month, showeed congestion⟶, inflammatory cells around the central vein ⇔ and necrotic cells●⟶ (H&E. 400x).

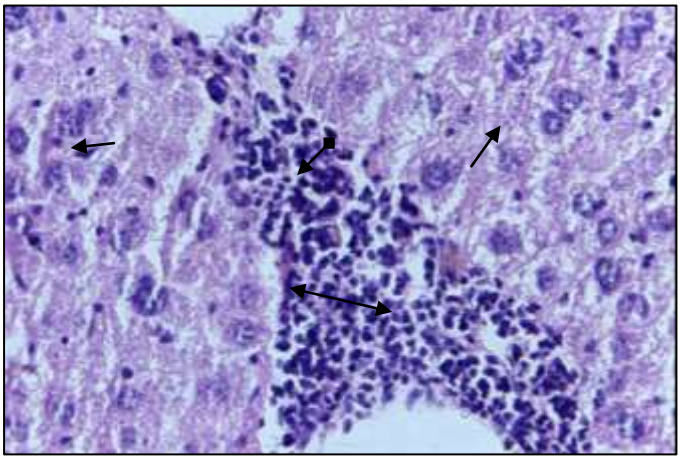

Fig.7: Histological section in liver of the animals treated with 50mg/kg.bw. of benzidine for 3 month, showed cell degeneration ⟶ and granuloma ⟷ (H&E. 400x).

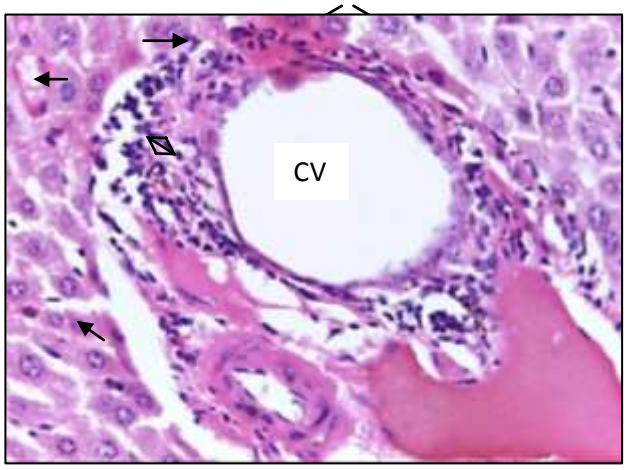

Fig.8: Histological section in liver of the animals treated with 50mg/kg.bw. of benzidine for 5 month, showed inflammatory cells ⟷ and cytoplasmic vaculation⟶ (H&E.400x).

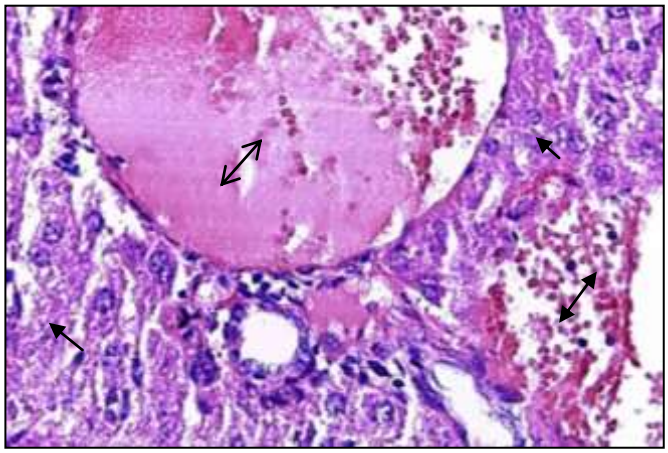

Fig.9: Histological section in liver of the animals treated with 100mg/kg.b.w. of benzidine for 3 month, showed cell degeneration → , hemorrhage ↔ and congestion in portal vein ⇔ (H&E. 400x).

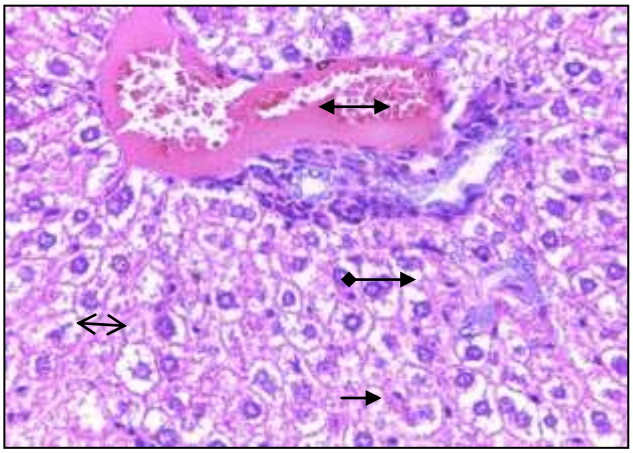

Fig.10 : Histological section in liver of the animals treated with 100mg/kg.b.w. of benzidine for 3 month, showed congestion in portal vein ↔ and cell degeneration → H&E.400x).

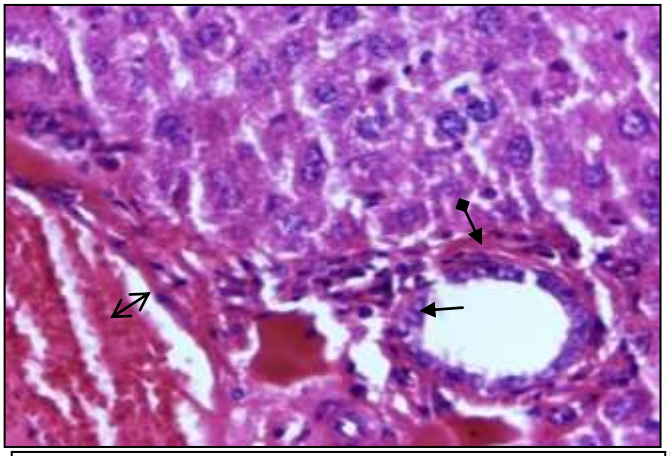

Fig.11: Histological section in liver of the animals treated with 50mg/kg.b.w. of benzidine for 5 month, showed collagenous fiber ◆→ and congestion ⇔ (H&E.400x).

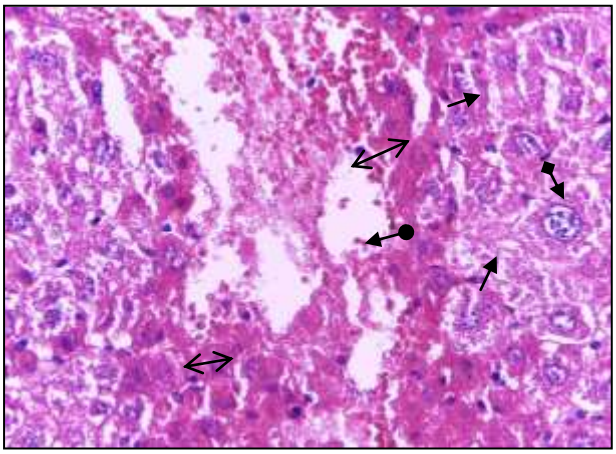

Fig.12: Histological section in liver of the animals treated 50mg/kg.b.w. of benzidine for 5 month, showed hemorrhage ⇔,necrotic cell ●→, more degeneration cells → and pycnotic ◆→ H&E.400x).

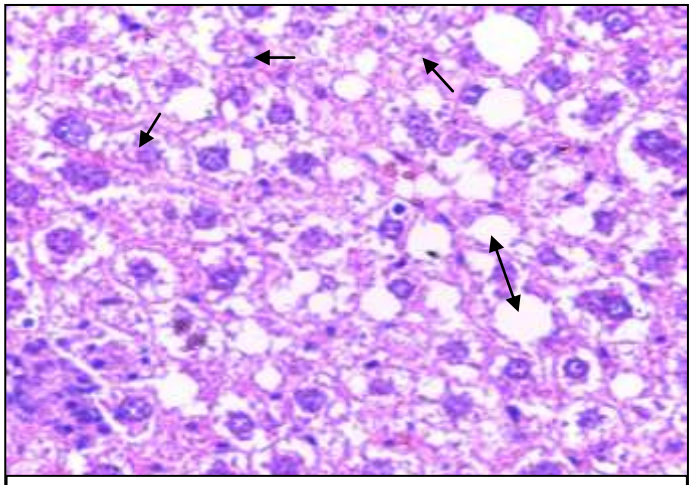

Fig.13: Histological section in liver of the animals treated with 50mg/kg.b.w. of benzidine for 5 month, showed cell degeneration → and fatty globules ↔ H&E. 400x).

2-**Histochemical examination:**

Histological examination of the liver animals treated with 25mg/kg.bw for 5 month showed densely mucus poly saccharide deposits in the hepotocyte cytoplasm and around the central vein compared with animals control (Fig.14,15 & 16), and observed more densely glycogen deposits in the hepotocyte cytoplasm in the liver animals treated with 50mg/kg. b.w.(Fig.17 & 18). While in the liver of animals treated with 100mg/kg.b.w. were showed more deposits around the central vein and portal vein(Fig.19&20).

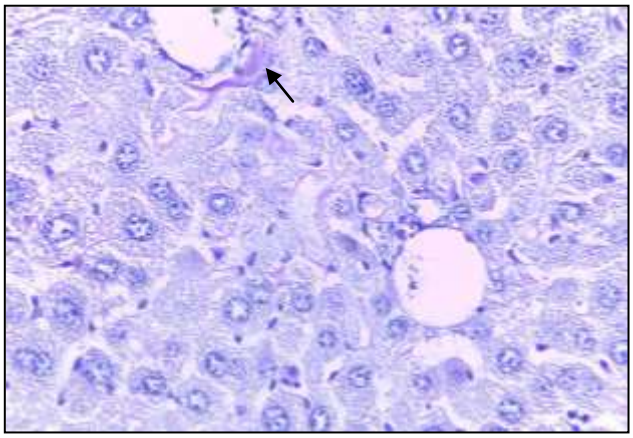

Fig.14: Histological section in liver of control mice, observed low densely of mucus poly saccharide deposits → (PAS.400x).

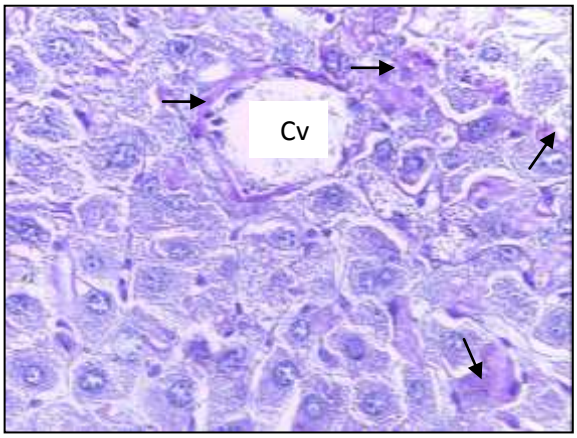

Fig.15:Histological section in liver of the animals treated with 25mg/kg.b.w. of benzidine for 5 month, observed densely of mucus poly saccharide deposits in the hepotocyte cytoplasm and around the central vein (cv) → . These accumulations are seen as pink (PAS. 400x).

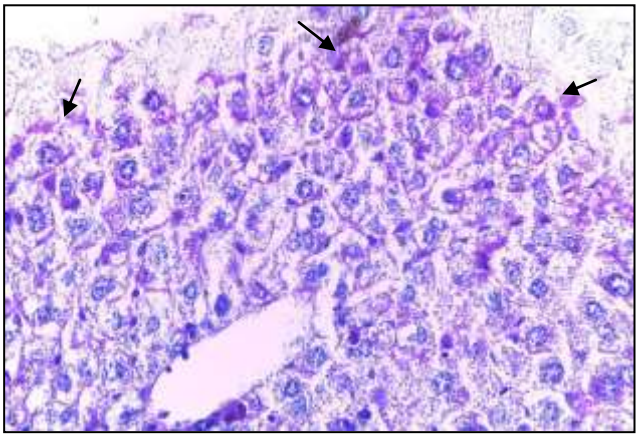

Fig.16:Histological section in liver of the animals treated with 25mg/kg.b.w. of benzidine for 5 month, observed densely of mucus poly saccharide deposits in the hepotocyte cytoplasm → . These accumulations are seen as pink (PAS. 400x).

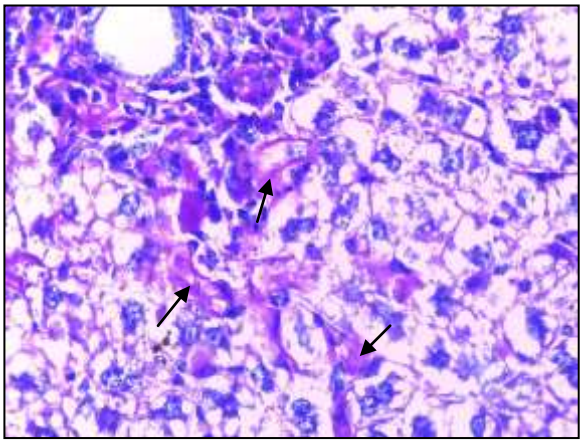

Fig.17:Histological section in liver of the animals treated with 50mg/kg.b.w. of benzidine for 5 month, observed more densely of mucus poly saccharide deposits in the hepotocyte cytoplasm →. These accumulations are seen as pink (PAS. 400x).

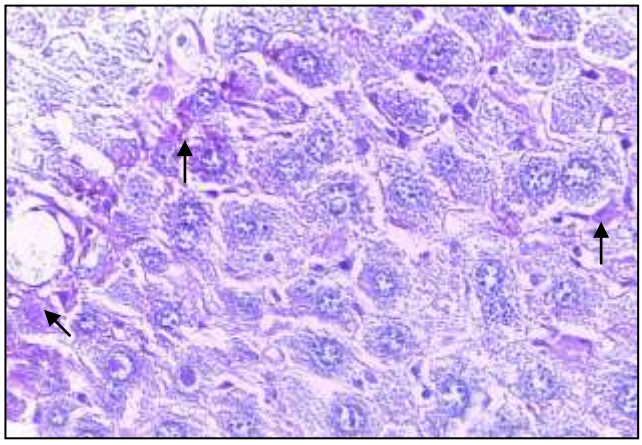

Fig.18:Histological section in liver of the animals treated with 50mg/kg.b.w. of benzidine for 5 month, observed densely of mucus poly saccharide deposits in the hepotocyte cytoplasm → . These accumulations are seen as pink(PAS.400x).

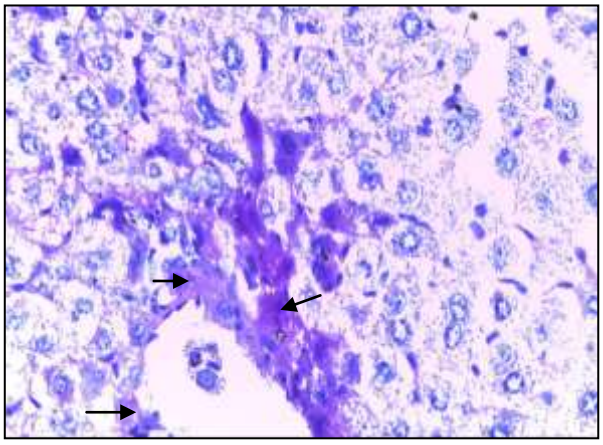

Fig.19:Histological section in liver of the animals treated with 100mg/kg.b.w. of benzidine for 5 month, observed densely of mucus poly saccharide deposits in the hepotocyte cytoplasm and more deposits around the central vein → . These accumulations are seen as pink(PAS.400x).

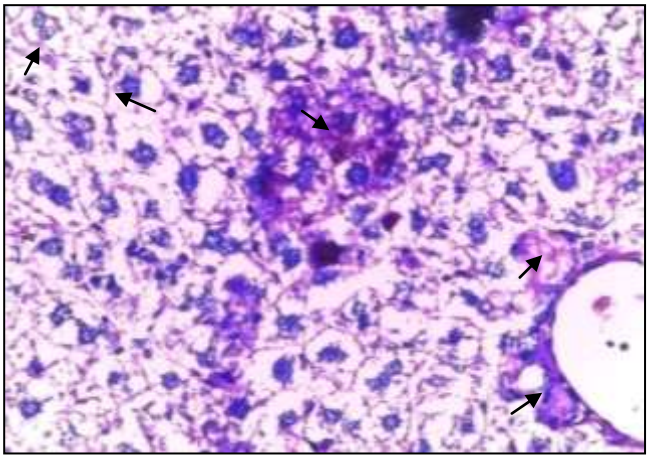

Fig.20:Histological section in liver of the animals treated with 100mg/kg.b.w. of benzidine for 5 month, observed densely of mucus poly saccharide deposits in the hepotocyte cytoplasm and deposits around the portal vein and deposits the plasma membrane →. These accumulations are seen pink (PAS.400x).

3-Cytogenitic examination:

The examination of bone marrow cells in metaphase stage of male mice treated with 25mg/kg.bw. of benzidine after 5 month, observed ring chromosomes, centromeric break and dicentric chromosome compared with animals control (Fig. 20, 21, 22 & 23), and observed chromosomal aberrations includes ring chromosome, centromeric break, dicentric chromosom and chromatid break in animals treated with 50mg/kg (Fig. 24 & 25). While in the bone marrow cells with animals treated with 100mg/kg showed centromeric break and chromatid break (Fig.26 & 27).

Fig.21: Giemsa-stained bone marrow metaphases of male mice, showed normal chromosomes 1000x

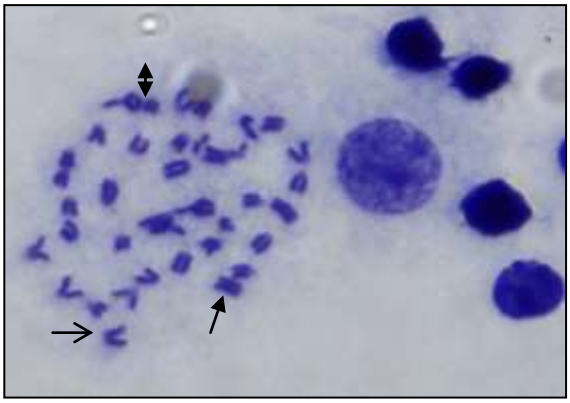

Fig.22: Giemsa-stained bone marrow metaphases of male mice treated with 25mg/kg. for 5 month, showed ring chromosomes ↔ , centromeric break → and dicentric chromosome → 1000x

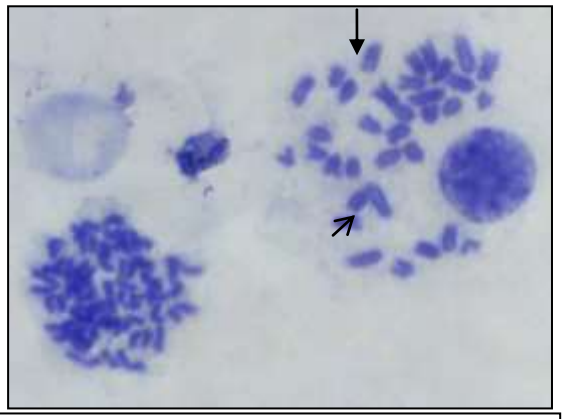

Fig.23: Giemsa-stained bone marrow metaphases of male mice treated with 25mg/kg. for 5 month, showed dicentric chromosome →.1000x

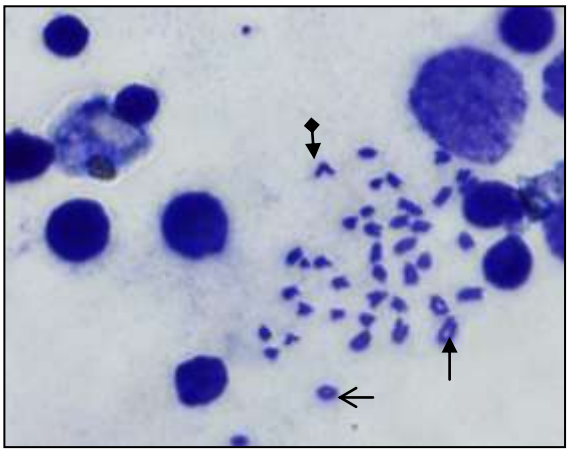

Fig.24: Giemsa-stained bone marrow metaphases of male mice treated with 50mg/kg. for 5 month, showed ring chromosomes → chromatid break ↔ and dicentric chromosome → .1000x

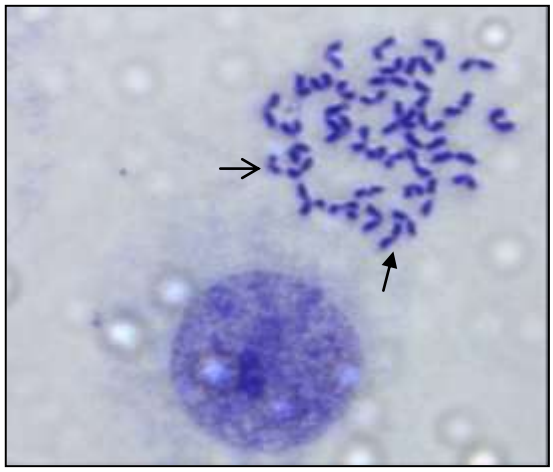

Fig.25: Giemsa-stained bone marrow metaphases of male mice treated with 50mg/kg. for 5 month, showed chromatid break → and centromeric break → .1000x

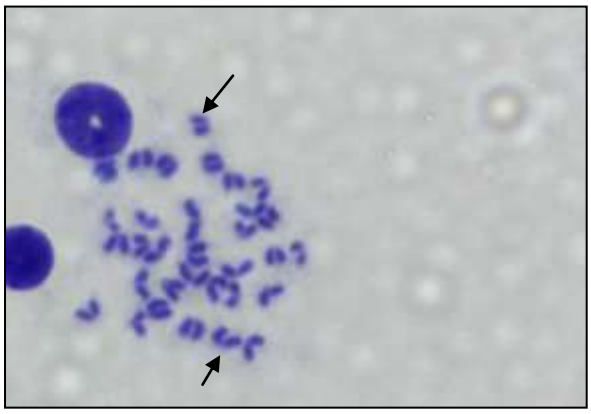

Fig.26: Giemsa-stained bone marrow metaphases of male mice treated with 100mg/kg. for 5 month, showed centromeric break → .1000x

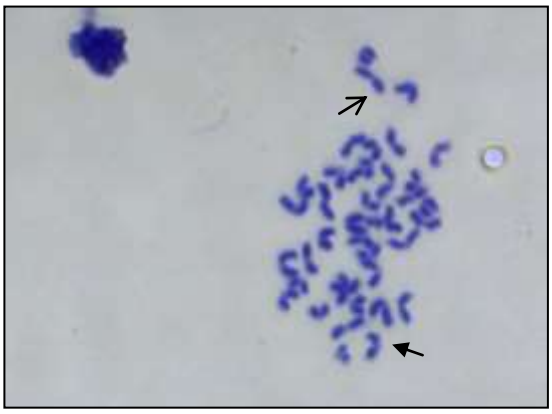

Fig.27: Giemsa-stained bone marrow metaphases of male mice treated with 100mg/kg. for 5 month, showed chromatid break → and centromeric break → .1000x

Discussion

In the present study liver histologic observations of the controle mouse showed radially arranged hepatic cords around the central vein. The histological study of liver of the male mice treated with (25, 50 & 100) mg/kg.bw. of benzidine for 3 &5 month showed infiltration of inflammatory cells, liver cells degeneration, vasodilatation in portal vein, thickening of bile duct wall, enlargement of the sinusoids, congestion, necrotic cells, granuloma, cytoplasmic vaculation, hemorrhage and appear collagenous fiber and fatty globules. Liver is a target organ and primary site of detoxification and is the major site of intense metabolism and is therefore prone to various disorders as a consequence of exposure to the toxins of extrinsic and intrinsic forms and plays important role in metabolism to maintain energy level and structural stability of body[12]. In the present study, the aggregation of inflammatory cells can be considered as a sign of an immune response, these inflammatory cells play an important role to the toxic metabolites of benzidine. These results are agreement with different previous researches which indicated that the exposure to chemicals led to induce sever phathologial and physiological and biochemical disturbances in experimental animals, mice and rabbits [13] and rats [14, 15]. Our result were in agreement with [16] who observed vacuolar degradation, nicrotic hepatocytes and infiltration of inflammatory cells from exposure rabbits of dichlorvus chemichal. [17, 18] reported that Acrylamide treatment in the liver of rats observed necrosis and bleeding, proliferation of sinusoidal bile ducts and hemorrhages.

[19] showed extensive histopathological lesions like hepatocytic enlargements, necrosis and fatty changes in rat and mice. In this study, we found deposits of mucus poly saccharide in mice treatment of benzidine for 5 month, These results are agreement with different studies , [20] who observed deposits of glycogen in hepatocytes from animals treatment with Auramine. In the present study investigation the benzidine treatment in the male mice induced chromosomes aberration in bone marrow cells, These results are agreement with different studies, [21], showed increased chromosomes aberration in lymphocyte cells of mice treatment with benzidine. [22], who observed ring chromosomes in rats bone marrow cells with treatment with tetrazine and suggests these effect resulting from DNA break and inhibitions of DNA Topoisomerase 11 enzyme.

References

(1) Schwenecke H, Mayer D (2005). Benzidine and Benzidine Derivatives. In: *Ullmann's Encyclopedia of Industrial Chemistry*, 7th Ed., New York, John Wiley & Sons, Inc., 18 pp. [2010 online database].

(2) IARC.(2010). General discussion of common mechanism for aromatic amines.International Agency for Research on Cancer.*IARC Monogr.Eval.Carcinog. Risks Hum* 99.

(3) ATSDR (2001). Toxicological Profile for Benzidine. Atlanta,GA: Agency for Toxic Substances and Disease Registry. *U.S. Public Health Service*: 242.

(4) NTP (2005). NTP 11th Report on Carcinogens. *Rep Carcinog 11:* 1–32.

(5) Littlefield, N.A.; Nelson,C.J. and Gaylor, D.W. (1984).Benzidinedihydrochloride risk assessment. *Fund. Appl.Toxicol*. 4:69-80.

(6) Morton KC ; Wang CY ; Garner CD and Shirai T. (1981). Carcinogenicity of benzidine, N,N'-diacetylbenzidine، and N-hydroxy-N,N'- diacetylbenzidine for female CD rats. Carcinogenesis, 2: 747–752. doi:10.1093/carcin/2.8.747 PMID:7285281.

(7) Xiang, C.Q. ; Shen, C.L.; Wu, Z.R. (2007). Detection of mutant p53 protein in workers occupationally exposed to benzidine. *Journal of Occupational Health* 49:279–284.

(8) Mirkova ET & Lalchev SG (1990). The genetic toxicity of the human carcinogens benzidine and benzidinebased dyes: chromosomal analysis in exposed workers.*Prog Clin Biol Res*, 340C: 397–405. PMID:2381938

(9) Wu Q & Heng ZC (2006). Study of rat's p53 gene damage and organ specificity induced by benzidine *Sichuan Da Xue Xue Bao Yi Xue Ban*, 37: 33–34, 39. PMID:16468636

(10) Culling, C.F.A. (1974). Hand book of histopathological and histochemical techniques, (3RD ED). Trowbridge and Esher publishers Redwood Burn Limited.pp712.

(11) Ackerman, S.L.(2013). A staff Scientist at the Jackson laboratory , Medical, Inst. Investigator. American biochemical research.

(12) Guyton AC and Hall JE. (2002). Text book of Medical Physiology ,9th ed . prism Book (Pvt) Ltd., Bangalore, India. Pp Xliii+1148.

(13) Yousef, F.M. El-Demerdash ; K. I. Kamal and K.S. Al-Salhen (2003). Changes in some hematological indices of rabbits induced by isoflavones and cypermethrin, Toxicology,vol.189.no.3,pp.223-234.

(14) Adeniran, O.Y. ; M.A. Fafunso, Adeyemi ; A.O. Lawal ; A. Ologundudu and A.A. Omonkhua (2006). Biochemical effects of pesticides on serum and urinological system of rats. J.Applied Sci., 6 : 668-672.

(15) Attia A.M. and Nasr H.M. (2009). Dimethoate-induced change in biochemical parametersof experimental rats serum. Slov.J. Anim. Sci.42 (2) : 87-94.

(16) Olatude, O. ; Fabian, V.E. ; Bukola, S.A.; Sheu, R; Effiong ,E.A.& Ganiya, .A.(2012).Histological changes in liver and lungs of rats exposed to dichlorvos before and after vitamin supplementation.*European journal of anatomy*3: 190-198.

(17) Nagao Totani Mino Yawata ; Yuko Ojiri and Yoshio fuzioka (2007). Effects of trace acrylamide intake in wistar rats, J.Oleo Sci 56(9), 501-506.

(18) Vasundhara, K. (2005). Characterization of rat glutathione S-transferases under the influence of methyl cholanthrene, Ph.D thesis, S.V. University, Tirupati, India.

(19) Koller L.D. ; B.V. Stang ; M.P. de la Paz ; and M.V. Ruiz Mendez (2001). Pathology of toxic oils and selected metals in the MRL/Ipr mouse, Toxic pathol 29(6), 630-638

(20) Mak (1985).Auramine, Auramine base**.**Section III A2MAK List.*The MAK Collection For Occupational Health And Safety* :25.

(21) Das, L. ; Das, S.K. ; Hooberman, B.H. ; Chu, E.H.; Sinsheimer, J.E (1994). Chromosomal aberrations in mouse lymphocytes exposed in vitro and in vivo to benzidine and 5 related aromatic amines.*Mutat. Res*. 320:69-74.

(22) Hassan ,G.M. (2010). Effects of some synthetic coloring additives on DNA damage and chromosomal aberrations of rats . *Arab J. Biotech.* 13:13-24.

دراسة نسجية وخلوية وراثية لتأثير البنزيدين في بعض أعضاء ذكور الفئران المختبرية البيض (*Mus muscularis*).

تبارك ليث عبد الصمد و كريم هلال ثامر
قسم علوم الحياة/ كلية العلوم _ جامعة البصرة

الخلاصة

اجريت الدراسة الحالية لإظهار التأثير السمي لمادة البنزيدين في ذكور الفئران (*Mus muscularis*). جرعت الحيوانات عن طريق غشاء البريتون مرة واحدة في بداية التجربة الى التراكيز(25 ، 50 و100) ملغم لكل كيلوغرام من وزن الجسم ولمدة (3 و5) شهرا. لوحظت تغيرات في نسيج الكبد ، شملت تحلل الخلايا الكبدية وارتشاح خلايا كفر واتساع الوريد البوابي بحيوانات السيطرة . كما أوضحت النتائج حدوث احتقان الوعاء الدموي وتوسع الجيبانيات الدموية وتنخر الخلايا وظهور الورم حبيبي والنزف الشديد وتفجي سايتوبلازم الخلايا ، فضلا عن ظهور الالياف الكولاجينية الممتدة داخل النسيج الكبدي وظهور القطيرات الدهنية وتنكس خلايا الكبد . كما بينت المقاطع النسجية ظهور زيادة تدريجية في ترسب السكريات المتعددة في خلايا الكبد اعتمادا على الجرعة المستخدمة. وأظهرت دراسة كروموسومات خلايا نقي العظم لذكور الفئران المعاملة بالتراكيز ولمدة خمسة أشهر حصول تشوهات كروموسومية تمثلت بحصول الكروموسومات الحلقية والكسرالسنتروميري والكروموسومات ذو السنتروميرين والكسر الكروماتيدي .